

AUG 2024

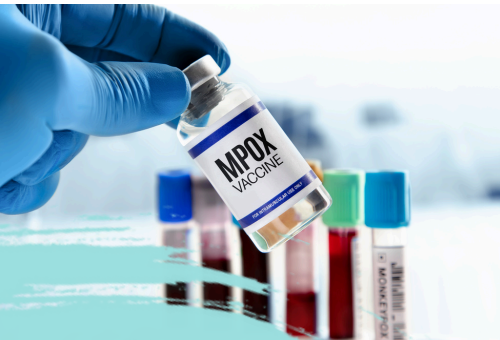MPOX UPDATE 2024

NEWSLETTER

Compiled by: Pro E Vardas & Dr Michelle Naidoo
Lancet Laboratories South Africa

TRANSMISSION

Various animal species are the natural hosts of this virus, small mammals such as Gambian rats, rope and tree squirrels, and some non-human primates.



Transmission from animal to humans (zoonotic) occurs from direct contact with the blood, bodily fluids, and cutaneous lesions of infected animals. Human to human transmission results from close contact, including sexual contact with skin.



Cerba Lancet
Zambia

Mpox in a nutshell

Mpox infection is caused by the monkeypox virus (MPXV), an enveloped double-stranded DNA virus of the Orthopoxvirus genus in the Poxviridae family. There are 2 distinct genetic clades, called clade I (formerly Central African clade) and clade II (formerly West African clade). Clade I is linked to more severe disease and a higher case fatality rate of approximately 10% (compared to 0.1% with clade II infections)

The 2022 – 2023 global outbreak of mpox was associated with a variant of clade II, called clade IIb, with cases mainly but not exclusively identified amongst men who have sex with men (MSM). During this time, South Africa saw five cases, all men aged 28 to 41 years, three of whom had recent travel from Switzerland, Spain and Netherlands.

The current mpox outbreak since 2023 in the Democratic Republic of the Congo (DRC) is linked to clade I and is mainly associated with sex workers. This DRC outbreak heralded the first documented sexual transmission of clade I and the first described transmission of clade I among the MSM community.

How are
we
Doing?

We value your opinion and would love to hear about your experience.

Do you have 2 minutes?

Let's Get Started

Scan our QRcode



Stand 2404 | Kabelenga Road | Lusaka | Zambia
Tel: +260 211 37480
Email: client.services.zambia@lancet.co.zm
Website: www.cerbalancetafrica.co.zm

Clinical

- The incubation period on average is 7 – 14 days (range 5 – 21 days). Asymptomatic infection has also been described. Initially the infection is characterised by fevers, myalgia, and lymphadenopathy. Rash or skin eruptions usually occur 1 – 3 days later.
- Location: The rash mainly occurs on the face, hands, feet, perioral areas including tongue, anogenital areas, trunk and sometimes the conjunctivae. Anogenital lesions may be associated with local oedema and features of proctitis (rectal pain, tenesmus, bleeding, discharge). Oral lesions may be associated with features of tonsillitis (sore throat, difficulty swallowing).
- Number: The number of lesions may vary from a few to hundreds and may coalesce to form large plaques or ulcers.
- Appearance: The rash is initially maculopapular, then evolves into vesicles, and thereafter into well circumscribed pseudopustules (not fluid or pus filled) which crust over with umbilication and finally desquamation and scarring (see Figure 1).
- In contrast to chickenpox (VZV), the rash is not itchy, lesions are not fluid/pus-filled, and all lesions are usually in the same stage of evolution. Additionally, lymphadenopathy is more likely to occur with mpox than with chickenpox.

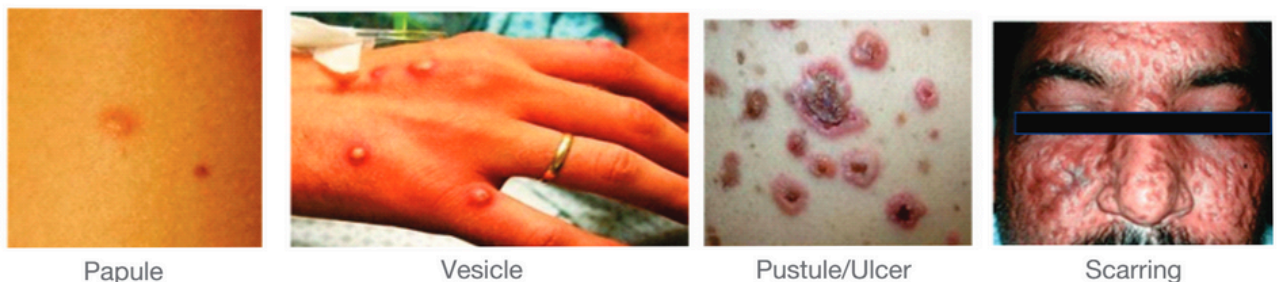


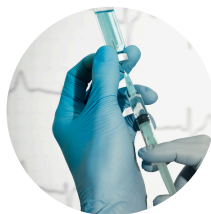Figure 1. Evolution of the Monkeypox rash

Monkeypox is a self-limiting disease resolving in 2-4 weeks with a low case fatality ratio ranging from 0-11%. Severe disease can occur in young children and those with underlying immune deficiencies from any cause. Vaccination with smallpox vaccine will not have this protection. disease can also occur in young children and those with underlying immune deficiencies from any cause, including uncontrolled HIV with a CD4 count of < 200 cells/ μ L. Vaccination with the smallpox vaccine offers a degree of protection from infection; however, individuals younger than 40 years who did not receive the smallpox vaccine will not benefit from this cross-protection.

Suspected mpox case definition (World Health Organization, March 2024)

A. A person who is a contact of a probable or confirmed mpox case in 21 days before the onset of signs or symptoms, and who presents with any of the following:

- Headache
- Acute onset of fever (>38.5 degrees)
- Lymphadenopathy
- Myalgia (muscle and body aches)
- Back pain
- Asehenia (profound weakness) or fatigue



B. A person presenting with:

- An unexpected acute rash
- Lymphadenopathy (swollen lymph nodes) OR
- Mucosal lesions
- AND
- For which the common causes of acute rash do not explain the clinical picture including varicella zoster, measles, zika, dengue, chikungunya, herpes simplex, primary or secondary syphilis, chancroid, lymphogranuloma venereum, molluscum contagiosum, bacterial skin infections, disseminated cryptococcosis, and allergic reactions.

N.B. It is not necessary to obtain negative laboratory results for the listed common causes of rash illness in order to classify a case as suspected. Probable mpox case definition (World Health Organization, March 2024)

Probable mpox case definition (World Health Organization, March 2024)

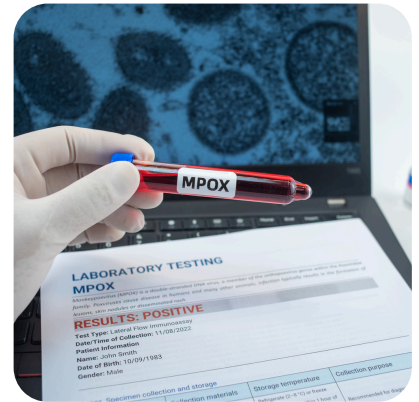
A person presenting with:

- An unexplained acute rash
- Lymphadenopathy (swollen lymph nodes)
- OR Mucosal lesions

AND

One or more of the following epidemiological links:

- Direct physical contact with a suspected or confirmed case of mpox in the last 21 days
- Contact with contaminated materials such as clothing, bedding or utensils from a probable or confirmed case of mpox in the last 21 days
- Travel history to an mpox endemic area in the last 21 days
- Identifies as gay, bisexual or man who has sex with other men
- Has had multiple and/or casual sexual partners in the last 21 days
- Has a positive Orthopoxvirus serology result in the absence of previous smallpox vaccination or other known exposure to orthopoxviruses



How is mpox diagnosed in the lab and what type of specimens are required?

Lancet Laboratories and the NICD currently offer PCR testing for the investigation of acute suspected mpox cases. Additionally, NICD also offers electron microscopy.

Mpox has two disease phases and different specimens can be collected in each phase.

During the prodromal phase, specimens to be collected include tonsillar tissue swab with a sterile dry swab, nasopharyngeal swab, acute serum and whole blood (not recommended).

During the rash/lesion phase, the best diagnostic specimens are taken directly from the rash including dry swab or swab in VTM of lesion exudate/aspirated fluid/biopsy, scab or crust. More than one lesion should be sampled via vigorous swabbing, preferably from different locations on the body and/or from different looking lesions. In the absence of skin lesions, swabs can be taken from the oropharyngeal, anal or rectal area.

During the prodromal phase, specimens to be collected include tonsillar tissue swab with a sterile dry swab, nasopharyngeal swab, acute serum and whole blood (not recommended).

During the rash/lesion phase, the best diagnostic specimens are taken directly from the rash including dry swab or swab in VTM of lesion exudate/aspirated fluid/biopsy, scab or crust. More than one lesion should be sampled via vigorous swabbing, preferably from different locations on the body and/or from different looking lesions. In the absence of skin lesions, swabs can be taken from the oropharyngeal, anal or rectal area.

References:

1. World Health Organization. Monkeypox, 18 April 2023. Available at: <https://www.who.int/news-room/fact-sheets/detail/monkeypox> [Accessed 14 May 2024]
2. World Health Organization. Multi-country monkeypox outbreak in non-endemic countries, 21 May 2022. Available at: <https://www.who.int/emergencies/disease-outbreak-news/item/2022-DON385> [Accessed 23 May 2022]
3. World Health Organization. Mpox (Monkeypox) outbreak toolbox, updated March 2024. Available at: <https://www.who.int/emergencies/outbreak-toolkit/disease-outbreak-toolboxes/mpox-outbreak-toolbox> [Accessed 14 May 2024]
4. National Institute of Communicable Diseases. Monkeypox. Available at: <https://www.nicd.ac.za/diseases-a-z-index/monkeypox/> [Accessed 14 May 2024]
5. Centers for Disease Control and Prevention. Monkeypox – Information for Clinicians. Available at: <https://www.cdc.gov/poxvirus/monkeypox/clinicians/index.html> [Accessed 14 May 2024]
6. World Health Organization. Mpox (monkeypox) - Democratic Republic of the Congo, 23 November 2023. Available at: <https://www.who.int/emergencies/disease-outbreak-news/item/2023-DON493>
7. Gessain A, et al. Monkeypox. N Engl J Med 2022; 387: 1783 – 1793. [Accessed 14 May 2024]
8. Mitjà O, et al. Mpox in people with advanced HIV infection: a global case series. Lancet 2023; 401(10380): 939 – 949.
9. Thornhill JP. Monkeypox Virus Infection in Humans across 16 Countries—April–June 2022. N Engl J Med 2022; 387: 679– 691